

CASE RECORDS of the MASSACHUSETTS GENERAL HOSPITAL

Founded by Richard C. Cabot

Nancy Lee Harris, M.D., *Editor*  
Jo-Anne O. Shepard, M.D., *Associate Editor*  
Sally H. Ebeling, *Assistant Editor*

Eric S. Rosenberg, M.D., *Associate Editor*  
Alice M. Cort, M.D., *Associate Editor*  
Christine C. Peters, *Assistant Editor*



## Case 31-2010: A 29-Year-Old Woman with Fever after a Cat Bite

Arnold N. Weinberg, M.D., and John A. Branda, M.D.

### PRESENTATION OF CASE

From the Division of Infectious Disease, Department of Medicine (A.N.W.), and the Department of Pathology (J.A.B.), Massachusetts General Hospital; and the Departments of Medicine (A.N.W.) and Pathology (J.A.B.), Harvard Medical School — both in Boston.

This article (10.1056/NEJMcpc1007103) was updated on November 24, 2010, at NEJM.org.

N Engl J Med 2010;363:1560-8.  
Copyright © 2010 Massachusetts Medical Society.

*Dr. Allyson K. Bloom (Infectious Disease):* A 29-year-old woman was admitted to the hospital because of fever after a cat bite.

The patient had been well until 5 days before admission, when, while working as a veterinarian's assistant at an animal hospital, she was bitten on the right thenar eminence by a domesticated cat, sustaining a single puncture wound. The cat, which had received rabies vaccinations in the past, had disappeared from its home for several days and had returned febrile, jaundiced, and anemic. After being bitten, the patient washed the wound and took one dose of amoxicillin, according to workplace protocol. She continued to work that day and handled cats, rabbits, guinea pigs, and dogs (including a dog with elevated results of liver-function tests and a history of leptospirosis). During the next 4 days, the patient cleaned cages, handled animals, and petted horses, sheep, and unvaccinated "barn cats" outside. She did not report that any animal licked her wound.

The day before admission, swelling, erythema, and pain developed over the volar radial surface of the patient's hand. The same day, the cat was euthanized because of progressive illness, and a specimen of the brain was sent for rabies testing. The next morning, throbbing pain developed in the patient's hand. She went to another hospital, where she rated the pain at 8 on a scale of 0 to 10, with 10 indicating the most severe pain. On examination, the vital signs were normal. The thenar eminence was red, hot, and swollen, with evidence of a small puncture wound; the range of motion of the joints was full, without pain, and there was no fluctuance. Ampicillin-sulbactam was given intravenously, and immunizations for diphtheria, tetanus, and pertussis were administered intramuscularly. Amoxicillin-clavulanic acid and oxycodone were prescribed, and the patient was discharged 2 hours after presentation, with instructions to follow up the next day, or sooner if the condition worsened. Approximately 9 hours later, she returned to the other hospital because of increasing pain (rated at 10 of 10) and swelling of the hand, difficulty moving her wrist, malaise, chills, neck pain, swollen lymph nodes, and subjective fever. On examination, the temperature was 37.7°C; other vital signs were normal. There was 1+ nonpitting edema on the right arm; edema and erythema were present over the thenar eminence, with proximal streaking and increased warmth. Range of motion at the wrist was normal. Right axillary lymph-

**Table 1. Hematologic and Serum Chemical Laboratory Data.**

Variable	Reference Range, Adults*	1st Admission to Other Hospital	1st Admission to This Hospital	2nd Admission to This Hospital
Hematocrit (%)	36.0–46.0 (women)	39	34.0	33.1
Hemoglobin (g/dl)	12.0–16.0 (women)	13.8	12.4	12.3
White-cell count (per mm <sup>3</sup> )	4500–11,000	8700	7900	6300
Differential count (%)				
Neutrophils	40–70	75	75	80
Lymphocytes	22–44	19	19	14
Monocytes	4–11	5	5	6
Eosinophils	0–8	1	1	0
Basophils	0–3	1	0	0
Platelet count (per mm <sup>3</sup> )	150,000–400,000	201,000	170,000	144,000
Sodium (mmol/liter)	135–145		135	135
Potassium (mmol/liter)	3.4–4.8		3.1	3.3
Chloride (mmol/liter)	100–108		103	103
Carbon dioxide (mmol/liter)	23.0–31.9		22.8	23.7
Protein (g/dl)				
Total	6.0–8.3			5.8
Albumin	3.3–5.0			3.4
Globulin	2.6–4.1			2.4
Alkaline phosphatase (U/liter)	30–100			124
Aspartate aminotransferase (U/liter)	9–32			181
Alanine aminotransferase (U/liter)	7–30			174
Heterophile antibody	Negative			Negative

\* Reference values are affected by many variables, including the patient population and the laboratory methods used. The ranges used at Massachusetts General Hospital are for adults who are not pregnant and do not have medical conditions that could affect the results. They may therefore not be appropriate for all patients.

adenopathy was present. The remainder of the examination was normal. Laboratory-test results are shown in Table 1. Morphine sulfate and another dose of ampicillin–sulbactam were administered intravenously, and ondansetron and oxycodone were given orally. Approximately 2 hours after presentation, the patient was discharged and driven to this hospital for further evaluation.

The patient was otherwise well. She had had a cesarean section 6 months earlier and lived with her partner and child, both of whom were healthy; she was monogamous with her partner. She drank alcohol socially, had smoked 10 cigarettes per day for 8 years, and did not use illicit drugs. She was taking no other medications and had no allergies. She owned cats, a dog, turtles, and a frog. She lived in a rural area of coastal

southeastern Massachusetts. Her only foreign travel had been to the Caribbean years earlier. She had been to southern California a year ago. She was not aware of having received any tick bites.

On examination, she appeared anxious and uncomfortable. The temperature was 37.1°C, the blood pressure 117/61 mm Hg, the pulse 102 beats per minute, the respiratory rate 16 breaths per minute, and the oxygen saturation 100% while she was breathing ambient air. The right hand, wrist, and axilla were tender, and the hand was swollen. A puncture wound was visible on the right thenar eminence, with surrounding erythema and red linear tracking on the ventral aspect of the wrist. There was right axillary lymphadenopathy. Sensation and peripheral puls-

es were normal, and there was no fluctuance that was suggestive of an abscess. The remainder of the examination was normal. A radiograph of the hand showed normal joint spaces and no foreign body. The level of glucose and tests of renal function were normal; other laboratory-test results are shown in Table 1. The patient was admitted to the observation unit. Morphine sulfate, ketorolac tromethamine, and ampicillin-sulbactam (third dose) were administered intravenously; acetaminophen was administered orally; and the hand was elevated. Pain in the hand decreased, and 12 hours after arrival, the patient was discharged with instructions to take amoxicillin-clavulanic acid twice daily for 10 days, to elevate her right hand at all times, and to seek medical follow-up in 3 days, or sooner if the condition worsened.

That evening, 6.5 hours after discharge from this hospital, the patient returned to the first

hospital because of shaking chills, a temperature of 40°C, headache, and generalized aching and arthralgias. On examination, the temperature was reportedly 38.5°C. Additional ampicillin-sulbactam, morphine, hydromorphone, diphenhydramine, and ondansetron were administered, and a splint was applied. In the morning, she was transferred by ambulance to this hospital, arriving 31 hours after her initial presentation at this hospital. She reported that the pain in the hand and wrist had improved; pain in the right arm, axilla, and neck had increased; and headache, diffuse body aches, mild abdominal and low pelvic pain, and transient numbness and tingling in the back and legs had developed. She reported no urinary symptoms.

The temperature was 39.0°C; other vital signs were stable. Erythema was decreased, cervical and axillary lymph nodes and the right hand were enlarged and tender, and the right hand

**Table 2. Results of Serologic Tests.**

Test	Reference Range	2nd Admission to This Hospital
Antibody to human immunodeficiency virus	Nonreactive	Nonreactive
Bartonella antibody		
<i>Bartonella henselae</i> IgG	Negative at <1:64 dilution	Negative
<i>B. henselae</i> IgM	Negative at <1:20 dilution	Negative
<i>B. quintana</i> IgG	Negative at <1:64 dilution	Negative
<i>B. quintana</i> IgM	Negative at <1:20 dilution	Negative
Leptospirosis antibody		
Leptospira IgM	Negative	Negative
Microagglutination	Negative (out of 20 serovars)	Negative (0 of 20 reacting)
Lyme antibody	Negative	Negative
Toxoplasma		
IgM	Negative	Negative
IgG	Negative	Negative
Rapid plasma reagin	Nonreactive	Nonreactive
<i>Francisella tularensis</i> antibody	Negative at <1:20 dilution, equivocal at 1:20 to 1:80, positive at 1:160	Negative at <1:20 dilution
<i>F. tularensis</i> microagglutination	Positive at 1:128 dilution	Presumed negative at 1:4 dilution
<i>Ehrlichia chaffeensis</i>		
IgM	Negative at <1:20 dilution	Negative at <1:20 dilution
IgG	Negative at <1:64 dilution	Negative at <1:64 dilution
<i>Anaplasma phagocytophilum</i>		
IgM	Negative at <1:20 dilution	Negative at <1:20 dilution
IgG	Negative at <1:64 dilution	Negative at <1:64 dilution

was edematous (2+), with decreased range of motion of the wrist and fingers. Levels of glucose and bilirubin were normal, as were the erythrocyte sedimentation rate and the results of renal-function tests. Urinalysis revealed 1+ ketones and trace urobilinogen and was otherwise normal. Tests for antibodies to hepatitis A and C viruses were negative; other test results are shown in Tables 1 and 2. Examination of Wright-stained smears of whole blood (thick and thin preparations) showed no evidence of intracellular or extracellular organisms or morulae. Chest radiographs showed minimal patchy airspace opacities in the middle lobe of the right lung, without focal consolidation, and abdominal ultrasonography was normal. Specimens of blood were cultured. Vancomycin, levofloxacin, morphine sulfate, ketorolac tromethamine, and normal saline were administered intravenously. Infectious-disease specialists were consulted, and the administration of ampicillin-sulbactam and azithromycin was begun. Her symptoms improved.

On the second hospital day, the administration of azithromycin was stopped, and doxycycline was begun. The swelling, pain, and erythema markedly diminished, and the temperature was normal. On the fourth day, the patient was discharged with instructions to take amoxicillin-clavulanic acid, doxycycline, and levofloxacin for 2 weeks.

At follow-up 7 weeks later, she felt well, and the physical examination was normal. A diagnostic test was performed.

#### DIFFERENTIAL DIAGNOSIS

*Dr. Arnold N. Weinberg:* I am aware of the diagnosis. The headline introducing this case could read, "Sick Cat Bites Healthy Veterinary Aid in Southeastern Massachusetts." After a fling in the rural outdoors, a domestic cat had returned home ill with fever, jaundice, and anemia. A healthy young woman in contact with multiple healthy pets at home and a variety of animals at work was bitten by the cat.

Several days later, an acute, painful cellulitis developed on the thenar area of the patient's hand at the site of the initial puncture wound. Although no fever was present, she was treated with ampicillin-sulbactam and amoxicillin-clavulanic acid. In response to the medication, the local cellulitis and pain were substantially di-

**Table 3. Bacterial Flora Commonly Associated with Humans.**

Normal
Staphylococcal species
Streptococcal species
Corynebacteria and diphtheroids
Anaerobes
Transient, from oral and respiratory sources
Staphylococci, including <i>Staphylococcus aureus</i>
Streptococci, including <i>Streptococcus pyogenes</i> and <i>S. milleri</i>
Anaerobes
Transient, from pets and veterinary clinic
Pasteurella species (especially <i>Pasteurella multocida</i> )
Bartonella species (especially <i>Bartonella henselae</i> )
Moraxella species
Staphylococcal and streptococcal species
Salmonella species

minished, without evidence of local complications, but nevertheless, chills and high fevers, pain in the whole arm and axillary nodes, headache, and generalized constitutional symptoms developed.

In reviewing this case, I have concluded that the patient most likely had a dual infection caused by the cat bite. After a puncture wound, an acute cellulitis developed that responded to broad-spectrum penicillins. This was followed by a subacute infection that was successfully treated with a combination of levofloxacin and doxycycline.

#### CELLULITIS

The initial acute painful cellulitis could have been polymicrobial and caused by organisms residing on the patient's skin or in the cat's mouth (Tables 3 and 4). The normal flora of the oral cavity of the domestic cat includes *Pasteurella multocida* and other bacteria, as well as pathogens that may be acquired from the environment or from mammals and birds that the cat may have come in contact with (Table 4).<sup>1</sup>

Although the initial process in this case is consistent with a streptococcal cellulitis, I would have expected a more acute onset, more fever, and a rapid resolution with penicillin therapy. Blood cultures were not available, and the initial cellulitis exudate was not sampled. The logical choice for the initial process remains *P. multocida*. This organism resides in the anterior oral cavity

**Table 4. Oral and Acquired Flora That May Be Associated with Cats.\***

Normal oral cavity
<i>Pasteurella multocida</i>
<i>Bartonella henselae</i>
Moraxella species
Staphylococci and streptococci
Anaerobes
Acquired from soil and water environment
Leptospira species
Listeria species
Nocardia species
<i>Francisella tularensis</i>
Mammals and birds
<i>Streptobacillus moniliformis</i>
<i>Erysipelothrix rhusiopathiae</i>
<i>Coxiella burnetii</i>
<i>F. tularensis</i>

\* These flora may cause disease in a cat or be transiently carried orally or on claws.<sup>1</sup>

of the cat and is the most frequent cause of infection, including painful cellulitis, from cat bites. For this reason, the routine protocol after a cat bite in veterinary practices consists of, at minimum, a single dose of amoxicillin. The powerful jaws and sharp canine teeth of the cat can easily pierce the skin and inject organisms into soft tissues, tendon sheaths, joint spaces, or even subperiosteal bone. None of these complications ensued. On clinical and statistical grounds, the pathogen *P. multocida* is the most likely cause of the initial mild fever and subsequent severe local pain and swelling that were consistent with cellulitis, without changed progression of the local puncture wound.<sup>2,3</sup>

#### SYSTEMIC INFECTION

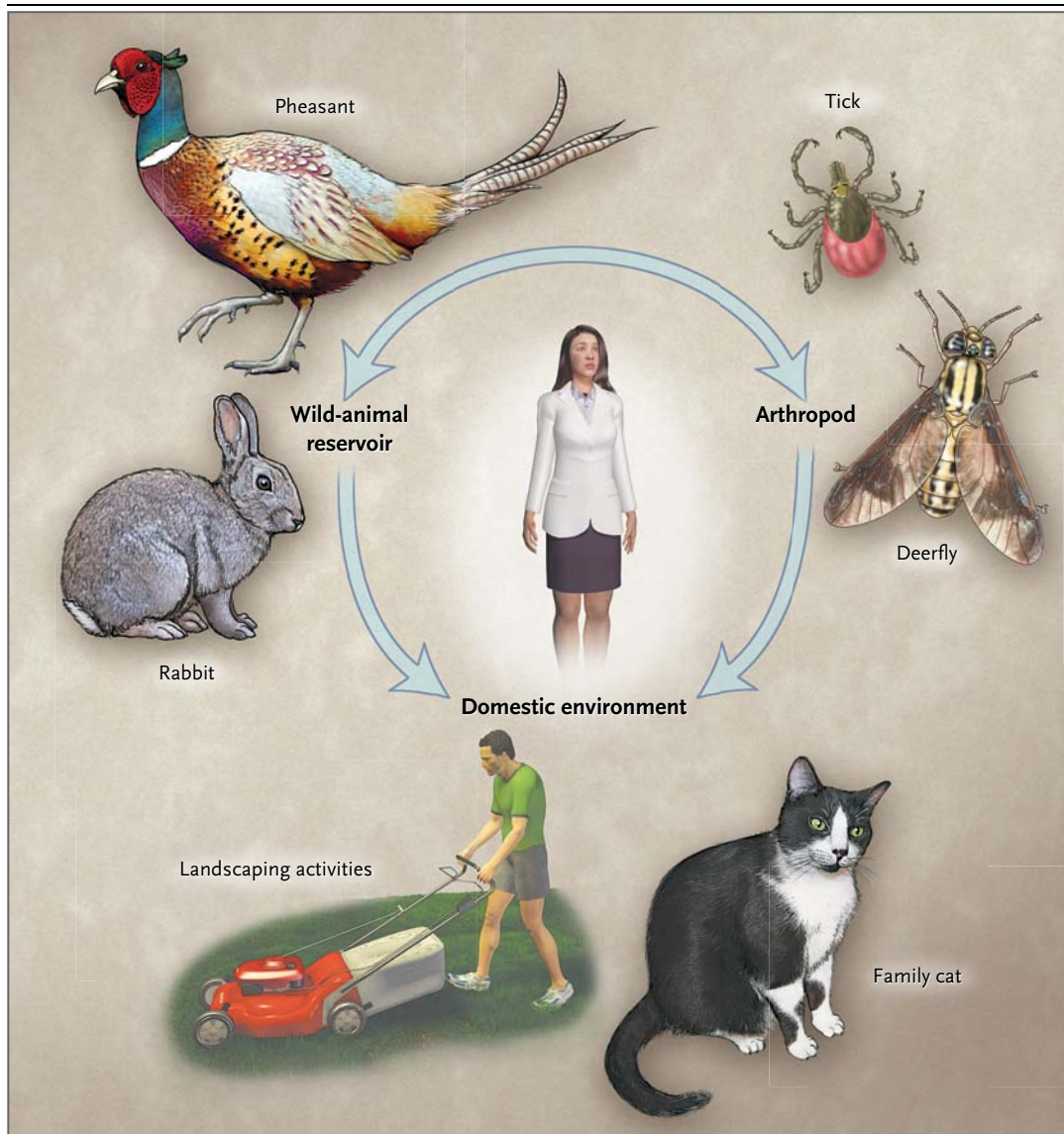
I assume that the cat was healthy, active, and curious when it wandered from home. During this period of freedom, it probably drank water wherever available, chased birds and small mammals (some of which were perhaps slowed by illness), and ingested tissue from a fresh kill or carcass. The list of potential pathogens acquired during this outdoor adventure includes several that could have resulted in the cat's acute illness and the patient's subacute illnesses that devel-

oped while she was on broad-spectrum penicillins (Table 4).<sup>1,4</sup>

The differential diagnosis should include pathogens from the environment and from living or dead mammals or birds. The cat could have become exposed to leptospira species by ingesting contaminated water. The acute illness in the cat is consistent with this diagnosis, but a cat bite is not a characteristic mode of transmission to humans, and the illness is not typically subacute. The same argument can be made for *Listeria monocytogenes*, which almost always follows ingestion and occasionally the inhalation of organisms and does not characteristically cause cellulitis or lymphadenitis, especially in immunocompetent hosts. *Nocardia* species, which contaminate soil, can cause a local cellulitis, often with nodular lymphangitis. The clinical characteristics of the cellulitis and the subacute systemic illness make this an unlikely diagnosis. Among pathogens that are associated with mammals and birds, *Erysipelothrix rhusiopathiae*, the cause of erysipeloid, and *Streptobacillus moniliformis*, the agent of rat-bite fever, should be mentioned. On rare occasions, these organisms have been associated with illness in cats, and they could be transmitted from the wild to a patient by a bite. However, erysipeloid is characterized by a superficial cellulitis with central clearing, and rat-bite fever by a generalized macular and papular rash.

The cat's acute illness and transmission of the causative agent to the patient through a bite is most compatible, in this geographic region, with *Francisella tularensis*. The patient's subacute illness, with high fever, headache, painful regional lymphadenopathy, generalized arthralgias, and mild liver-function abnormalities, is characteristic of infection with *F. tularensis*, as was the response to treatment with levofloxacin and doxycycline. This highly successful pathogen can persist for months in nature in mud, water, and mammal or bird carcasses. It can be spread to humans by ingestion, inhalation, tick and deer-fly bites, contact with infected tissues, or an animal bite. In the United States between 2000 and 2008, an average of 125 cases per year was reported to the Centers for Disease Control and Prevention (CDC); the highest prevalence was in Missouri, Arkansas, Oklahoma, and Massachusetts ([www.cdc.gov/tularemia](http://www.cdc.gov/tularemia)). Of the average of 10 cases per year in Massachusetts, the majority





**Figure 1. The transmission of *Francisella tularensis*.**

*F. tularensis* is maintained in nature by interactions between animals and the ticks and flies that bite them. In recent years, more cases have been reported in humans from ticks and deerflies than from direct contact with wild animals. Spread occurs from wild-animal reservoirs to domestic animals, especially cats, and transmission to humans results from animal or insect bites, the handling of infected animal tissues, or inhalation of aerosolized organisms during activities such as landscaping or lawn mowing.

have occurred in southeastern coastal regions, particularly on the island of Martha's Vineyard.<sup>5</sup> Approximately 75% of cases of tularemia in the United States are manifested by a tender regional lymph node and a local papule that evolves to a chancreiform lesion; such cases are referred to as ulceroglandular tularemia. In a small number of cases, there is a local lesion without enlargement of a regional node<sup>6</sup> (especially in arthro-

pod-transmitted disease) or regional lymphadenopathy without a local cutaneous lesion. An acute, painful cellulitis is not characteristic of tularemia and was the clue that suggested the diagnosis of two distinct infections caused by the cat bite. Typhoidal and pneumonic tularemia are less common manifestations and account for most fatalities.<sup>5</sup>

In cat-associated tularemia,<sup>7,8</sup> the cat can be

well or can have an acute illness, and it can transmit the organism to humans via a bite or scratch. Transmission is highly effective — a small number of organisms (10 to 50 colony-forming units) is sufficient to cause disease in humans — so *F. tularensis* is considered a possible agent of bioterrorism.<sup>9</sup> Recent molecular genetic studies have improved our understanding of the incidence, geographic distribution, and virulence of *F. tularensis*<sup>8</sup> (Fig. 1). Of the two subspecies of *F. tularensis*, type A (*F. tularensis tularensis*) is most commonly associated with infections in rabbits and cats, and type B (*F. tularensis holarctica*) is more prevalent in rodents. Genotype A1 predominates in the eastern United States, and genotype A1b is associated with most fatal cases of tularemia in humans.<sup>8</sup> In summary, I believe that a dual diagnosis in this case involved an initial cellulitis due to *P. multocida* and a subsequent local and systemic illness caused by *F. tularensis* after a bite from a sick cat.

**Dr. Eric S. Rosenberg (Pathology):** Dr. Bloom, can you tell us what the care team was thinking at the time, and what the diagnostic test was?

**Dr. Bloom:** We thought the patient might have acquired a superinfection during her handling of other animals in the days subsequent to the cat bite. We also suspected a systemic infection due to leptospirosis, *F. tularensis*, toxoplasmosis, bartonella, or ehrlichia. We sent serum from the convalescent phase for testing for antibodies to these organisms, 7 weeks after discharge.

---

#### CLINICAL DIAGNOSIS

---

Systemic infection due to a cat bite, possibly leptospirosis, *F. tularensis*, toxoplasmosis, bartonella, or ehrlichia.

---

#### DR. ARNOLD WEINBERG'S DIAGNOSIS

---

Acute cellulitis due to *P. multocida*, followed by glandular and systemic infection with *F. tularensis* (tularemia), both after a cat bite.

---

#### PATHOLOGICAL DISCUSSION

---

**Dr. John A. Branda:** On admission to this hospital, two sets of routine blood cultures were inoculated. In addition, a blood culture subjected to a lysis–centrifugation technique was collected the

following day. All blood cultures were incubated for 21 days, at the request of the ordering physician, to detect fastidious, slowly growing bacteria, especially francisella species. Despite the extended incubation, all cultures were negative. Notably, pasteurella was not isolated; however, the cultures were collected after initiation of effective antimicrobial therapy.

The diagnostic specimen in this case was serum collected for detection of antibodies directed against *F. tularensis*. Tube agglutination and microagglutination are the standard methods for serodiagnosis<sup>10</sup>; this patient's serum was tested at the State Laboratory Institute of the Massachusetts Department of Public Health by the microagglutination method. Agglutination methods do not separately determine class-specific antibodies, as can more current testing formats such as enzyme-linked immunosorbent assays, but this is immaterial in serodiagnostic testing for tularemia. One of the idiosyncrasies of the antibody response in tularemia is that IgM, IgA, and IgG isotypes appear simultaneously, usually during the second or third week after infection.<sup>10,11</sup> Moreover, all three isotypes can be seen well into convalescence, often persisting for years after successful treatment.<sup>12,13</sup> Therefore, the presence of IgM antibodies does not reveal whether exposure was recent or remote.<sup>10</sup> In addition, antibody titers are similar for the various clinical forms of tularemia and for cases of differing severity.<sup>11</sup>

The patient's serum, collected the day after admission during the acute phase, was negative for tularemia at a microagglutination titer of 1:4 (diagnostic titer for this test method, 1:128). Her serum, collected approximately 7 weeks later during the convalescent phase, was positive at a microagglutination titer of 1:1024. These findings established the pathological diagnosis of tularemia in this patient, since an increase in the serum antibody titer by a factor of four or more is diagnostic.<sup>10,14,15</sup> This test detects antibodies to all subtypes of *F. tularensis* and does not discriminate among the genotypes.

The patient also had IgG antibodies to *Bartonella henselae*, a feature suggestive of past infection, probably by means of occupational exposures. Since blood cultures were negative and the site of infection was not cultured, the suggestion of a mixed infection including cellulitis due to *P. multocida* remains a clinical diagnosis in this case.

## MANAGEMENT

*Dr. Rosenberg:* Dr. Weinberg, how would you have managed this patient's illness?

*Dr. Weinberg:* In recognizing that *P. multocida* is the most common infection that occurs after a cat bite, treatment with a broad-spectrum penicillin, such as amoxicillin-clavulanic acid, is appropriate. In addition to being the medication of choice for *P. multocida*, its spectrum of treatment includes many of the skin organisms of the person bitten and mouth flora of the cat. Doxycycline can be given to persons who are allergic to penicillin.<sup>16</sup>

Treatment of *F. tularensis* has traditionally involved either streptomycin or, more recently, gentamicin. Oral therapy with doxycycline and ciprofloxacin, extending for a minimum of 3 weeks to avoid treatment failure, has been successful, as it was in this patient.<sup>6,17</sup>

*Dr. Rosenberg:* Dr. Bloom, would you tell us what happened with this patient?

*Dr. Bloom:* When we initially saw her, the patient appeared to be responding to levofloxacin. Since we were not entirely confident that tularemia was the sole diagnosis, we also treated her with doxycycline for 2 weeks. At follow-up 7 weeks after discharge, she was well. Her hand had completely healed, and she had no lymphadenopathy. At that visit, we sent the serum from the convalescent phase for testing, which confirmed the diagnosis of tularemia.

*Dr. Weinberg:* This case reminds us that zoonotic diseases appear after interactions with domestic as well as wild animals. Cats are an important vector for human infection with the most virulent strain of *F. tularensis* (type A1b). Veterinarians and physicians who work in areas

where this strain is found need to be aware of its pathogenicity.<sup>8</sup> This case highlights the importance of careful environmental and occupational history taking of patients with suspected infectious diseases, and it also emphasizes the need for better communication between veterinarians and physicians.

*Dr. Thomas R. Spitzer (Hematology):* What is the expected evolution of tularemia if the diagnosis is not made properly or if proper treatment is not given?

*Dr. Weinberg:* The severity of the disease is influenced by the type and strain of the organism and by the route of transmission. Type A1 is invasive and virulent, especially genotype A1b.<sup>8</sup> Ulceroglandular disease may persist for weeks to months, with minor constitutional symptoms. In the western United States, where types A2 and B are more common than type A1, mortality may be very low, even without early diagnosis and treatment. However, on the East Coast, where type A1b is prevalent, the likelihood of fatal systemic disease if the diagnosis is not made promptly is probably greater. A recent study showed that type A1b infections were associated with a mortality rate of 24%, but the details of early diagnosis and treatment make the percentage uncertain.<sup>8</sup>

## ANATOMICAL DIAGNOSIS

Infection with *Francisella tularensis* (tularemia).

This case was presented at the Medical Case Conference, May 1, 2009.

Dr. Branda reports receiving grants from TBS Technologies and DiaSorin. No other potential conflict of interest relevant to this article was reported.

Disclosure forms provided by the authors are available with the full text of this article at NEJM.org.

## REFERENCES

1. Kotton CN, Weinberg AN. Zoonoses. In: Mandell GL, Bennett JE, Dolin R, eds. Mandell, Douglas, and Bennett's principles and practice of infectious diseases. 7th ed. Vol. 2. Philadelphia: Churchill Livingstone Elsevier, 2010:3999-4007.
2. Talan DA, Citron DM, Abrahamian FM, Moran GJ, Goldstein EJC. Bacteriologic analysis of infected dog and cat bites. *N Engl J Med* 1999;340:85-92.
3. Zurlo JJ. *Pasteurella* species. In: Mandell GL, Bennett JE, Dolin R, eds. Mandell, Douglas, and Bennett's principles and practice of infectious diseases. 7th ed. Vol. 2. Philadelphia: Churchill Livingstone Elsevier, 2010:2939-42.
4. Westling K, Farra A, Cars B, et al. Cat bite wound infections: a prospective clinical and microbiological study at three emergency wards in Stockholm, Sweden. *J Infect* 2006;53:403-7.
5. Nigrovic LE, Wingenter SL. Tularemia. *Infect Dis Clin North Am* 2008;22:489-504.
6. Feldman KA. Tularemia. *J Am Vet Med Assoc* 2003;222:725-30.
7. Capellan J, Fong IW. Tularemia from a cat bite: case report and review of feline-associated tularemia. *Clin Infect Dis* 1993;16:472-5.
8. Kugeler KJ, Mead PS, Janusz AM, et al. Molecular epidemiology of *Francisella tularensis* in the United States. *Clin Infect Dis* 2009;48:863-70.
9. Ellis J, Oyston PC, Green M, Titball RW. Tularemia. *Clin Microbiol Rev* 2002;15:631-46.
10. Lindquist D, Chu MC, Probert WS. *Francisella* and *Brucella*. In: Murray PR, ed. Manual of clinical microbiology. 9th ed. Vol. 1. Washington, DC: ASM Press, 2007:815-34.
11. Syrjälä H, Koskela P, Ripatti T, Salminen A, Herva E. Agglutination and ELISA methods in the diagnosis of tularemia in different clinical forms and severities of the disease. *J Infect Dis* 1986;153:142-5.



12. Bevanger L, Maeland JA, Kvan AI. Comparative analysis of antibodies to *Francisella tularensis* antigens during the acute phase of tularemia and eight years later. *Clin Diagn Lab Immunol* 1994;1: 238-40.
13. Ericsson M, Sandström G, Sjöstedt A, Tärnvik A. Persistence of cell-mediated immunity and decline of humoral immunity to the intracellular bacterium *Francisella tularensis* 25 years after natural infection. *J Infect Dis* 1994;170: 110-4.
14. Tärnvik A, Chu MC. New approaches to diagnosis and therapy of tularemia. *Ann N Y Acad Sci* 2007;1105:378-404.
15. Spletstoesser WD, Tomaso H, Al Dahouk S, Neubauer H, Schuff-Werner P. Diagnostic procedures in tularaemia with special focus on molecular and immunological techniques. *J Vet Med B Infect Dis Vet Public Health* 2005;52:249-61.
16. Goldstein EJ. Current concepts on animal bites: bacteriology and therapy. *Curr Clin Top Infect Dis* 1999;19:99-111.
17. Pérez-Castrillón JL, Bachiller-Luque P, Martín-Luquero M, Mena-Martín FJ, Heróles V. Tularemia epidemic in northwestern Spain: clinical description and therapeutic response. *Clin Infect Dis* 2001;33: 573-6.

Copyright © 2010 Massachusetts Medical Society.

**LANTERN SLIDES UPDATED: COMPLETE POWERPOINT SLIDE SETS FROM THE CLINICOPATHOLOGICAL CONFERENCES**

Any reader of the *Journal* who uses the Case Records of the Massachusetts General Hospital as a teaching exercise or reference material is now eligible to receive a complete set of PowerPoint slides, including digital images, with identifying legends, shown at the live Clinicopathological Conference (CPC) that is the basis of the Case Record. This slide set contains all of the images from the CPC, not only those published in the *Journal*. Radiographic, neurologic, and cardiac studies, gross specimens, and photomicrographs, as well as unpublished text slides, tables, and diagrams, are included. Every year 40 sets are produced, averaging 50-60 slides per set. Each set is supplied on a compact disc and is mailed to coincide with the publication of the Case Record.

The cost of an annual subscription is \$600, or individual sets may be purchased for \$50 each. Application forms for the current subscription year, which began in January, may be obtained from the Lantern Slides Service, Department of Pathology, Massachusetts General Hospital, Boston, MA 02114 (telephone 617-726-2974) or e-mail [Pathphotoslides@partners.org](mailto:Pathphotoslides@partners.org).