

This ArticleExtract **FREE**[PDF of print issue](#)[Respond to this article](#)[Alert me when this article is cited](#)[Alert me when responses are posted](#)[Alert me when a correction is posted](#)[View citation map](#)**Services**[Email this article to a friend](#)[Find similar articles in BMJ](#)[Find similar articles in PubMed](#)[Add article to my folders](#)[Download to citation manager](#)[Request Permissions](#)**Google Scholar**[Articles by Khan, A.](#)**PubMed**[PubMed Citation](#)[Articles by Khan, A.](#)**Related Content**[Calcium and bone](#)[Musculoskeletal syndromes](#)[Dentistry and oral medicine](#)[Surgical oncology](#)[Osteoporosis](#)**Bookmark with**

Published 2 February 2010, doi:10.1136/bmj.c246

Cite this as: BMJ 2010;340:c246

Editorials

Osteonecrosis of the jaw and bisphosphonates

Low doses for osteoporosis seem to be safe

Bisphosphonate associated osteonecrosis of the jaw is defined as exposed bone in the maxillofacial region for more than eight weeks in the absence of radiotherapy but the presence of bisphosphonate use. The condition is diagnosed clinically with exclusion of local malignancy. Other conditions may present in a similar manner, and these include spontaneous sequestration or lingual mandibular sequestration and ulceration, which is characterised by exposed necrotic bone at the level of the mylohyoid ridge of the lingual mandible. This condition is self limiting and heals spontaneously within three days to 12 weeks.¹

Other important risk factors for the development of osteonecrosis include local infection, chemotherapy, steroid use, trauma, and periodontal disease.² Bisphosphonates are commonly used in the management of skeletal complications of malignancy, and treatment with high dose bisphosphonates has been associated with an increased risk of osteonecrosis of the jaw in patients with cancer.^{3 4 5 6 7} In this population, the estimated incidence of osteonecrosis is between 1% and 15%, and it seems to be related to the dose and duration of bisphosphonate treatment.

In patients with osteoporosis, much lower doses of bisphosphonates are used, and a causal link has not been established between low dose oral or intravenous bisphosphonates and osteonecrosis of the jaw.⁸ The incidence seems to be between 1 in 10 000 and less than 1 in 100 000 person years of exposure,^{9 10} which may be similar to the incidence seen in the general population.¹¹

With increased awareness of bisphosphonate associated osteonecrosis of the jaw, cases of spontaneous ulceration are possibly being misclassified as this condition. Further prospective data are needed to quantify the incidence of osteonecrosis of the jaw in the general population and in those receiving high and low dose bisphosphonates.

Multiple factors have been implicated in the development of osteonecrosis of the jaw. The exact mechanism by which high doses of bisphosphonates increase the risk is not fully understood. Local trauma caused by a tooth extraction in the presence of impaired osteoclast function (which can be the result of several factors) may cause inadequate clearance of necrotic debris. Secondary infection may also facilitate the development of local




What's new

- Last 7 days
- Past weeks
- Current print issue
- Rapid responses

Latest blogs


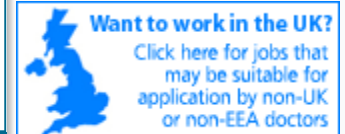- Gateshead to Guatemala
- What we're reading
- 5 storeys up
- What makes a good doctor?
- Richard Lehman on doc2doc

Find BMJ on:

-  Latest from BMJ
-  BMJ simple search
-  Follow BMJ on twitter

Services

- Blogs
- Podcasts
- Submit an article
- Subscribe/Activate
- Email alerts
- Request permissions

Tools[Email to friend](#) [Print this page](#)  [RSS](#)**Online poll****Has guideline development gone astray?**



What's this?

osteonecrosis. Bisphosphonates may have toxic effects on local soft tissue and impair the function of epithelial and vascular cells, which may prevent soft tissue healing and closure after dental surgery and contribute to the development of local osteonecrosis.¹² Osteonecrosis of the jaw can present with local pain, soft tissue swelling, and inflammation, which can progress to fistulas and pathological fractures.

International strategies on prevention and treatment exist, but they are based on expert opinion and anecdotal evidence because of the lack of prospective data. Recommendations emphasise the importance of an oral examination with radiographic visualisation of the mandible and maxilla before starting high dose bisphosphonates in patients with cancer. Treatment may need to be interrupted in the presence of a dental emergency, and this situation should be managed by the medical, dental, and oncology team.

Regarding prevention, it is important to emphasise good oral hygiene and semiannual dental assessment in all patients taking bisphosphonates. Patients should also be encouraged to stop smoking and limit alcohol intake. If possible, any necessary dental work should be completed before starting treatment with bisphosphonates. If a dental procedure is necessary, bisphosphonates should ideally be discontinued three months before the procedure and resumed after the surgical site has healed. Bisphosphonates should be stopped immediately before an emergency dental procedure and resumed once the surgical site has healed.⁸

Treatment of osteonecrosis of the jaw focuses on treating secondary infections, providing suitable analgesia, and ensuring appropriate nutritional intake—tube feeding should be considered if the oral lesions prevent food intake. Surgery is reserved for removal of necrotic debris with limited debridement. Further prospective studies are needed to provide evidence based guidelines on the prevention and management of this uncommon condition.

Cite this as: *BMJ* 2010;340:c246

Aliya Khan, professor of clinical medicine

¹ McMaster University, 331 #209 Sheddon Avenue, Oakville, ON, Canada, L6J 5T4

aliya@mcmaster.ca

Competing interests: The author has completed the Unified Competing Interest form at www.icmje.org/coi_disclosure.pdf (available on request from the corresponding author) and declares: (1) No financial support for the submitted work from anyone other than the employer; (2) AK has served on the board of and consulted for Amgen, Lilly, Novartis, NPS, and Servier; AK has also received grants, honorariums, speaking expenses, and travel expenses from Amgen, Lilly, Merck, Novartis, NPS, Proctor and Gamble, and Servier; (3) No spouses, partners, or children with relationships with commercial entities that might have an interest in the submitted work; (4) No non-financial interests that may be relevant to the submitted work.

Provenance and peer review: Commissioned; not externally peer reviewed.

References

1. Peters E, Lovas GL, Wysocki GP. Lingual mandibular sequestration and ulceration. *Oral Surg Oral Med Oral Pathol* 1993;75:739-43. [\[CrossRef\]](#)[\[Web of Science\]](#)[\[Medline\]](#)
2. Khosla S, Burr D, Cauley J, Dempster DW, Ebeling PR, Felsenberg D, et al. Bisphosphonate associated osteonecrosis of the jaw: report of a task force of the American Society for Bone and Mineral Research. *J*

Yes

No

[View Results](#)

[Share This](#)

[Vote](#) ✓

[Find out more>>](#)

Resources

- Readers
- Authors
- Reviewers
- Media
- BMA members
- Advertising and sponsors
- Subscribers

Rapid responses for this article

There are no rapid responses for this article.

Print issues

- Current issue contents
- Current cover image
- Past issues
- Subscribe



- et al. Bisphosphonate associated osteonecrosis of the jaw: report of a task force of the American Society for Bone and Mineral Research. *J Bone Miner Res* 2007;22:1479-91.[CrossRef]
3. Tosi P, Zamagni E, Cangini D. Bisphosphonates and osteonecrosis of the jaw: incidence in a homogenous series of patients with newly diagnosed multiple myeloma treated with zoledronic acid. *Blood* 2005;106:3467a.
 4. Durie BG, Katz M, Crowley J. Osteonecrosis of the jaws and bisphosphonates. *N Engl J Med* 2005;353:99-102.[Free Full Text]
 5. Cartos VM, Zhu S, Zavras AI. Bisphosphonate use and the risk of adverse jaw outcomes: a medical claims study of 714 217 people. *J Am Dent Assoc* 2008;139:23-30.[Abstract/Free Full Text]
 6. Bamias A, Dimopoulos MA. Thalidomide and immunomodulatory drugs in the treatment of cancer. *Exp Opin Invest Drugs* 2005;14:45-55. [CrossRef]
 7. Dimopoulos MA, Kastritis E, Anagnostopoulos A, Melakopoulos I, Gika D, Mouloupoulos LA, et al. Osteonecrosis of the jaw in patients with multiple myeloma treated with bisphosphonates: evidence of increased risk after treatment with zoledronic acid. *Haematologica* 2006;91:968-71.[Abstract/Free Full Text]
 8. Khan AA, Sandor GK, Dore E, Morrison AD, Alshali M, Amin F, et al. Canadian consensus practice guidelines for bisphosphonate associated osteonecrosis of the jaw. *J Rheumatol* 2008;35:1391-7. [Abstract/Free Full Text]
 9. Felsenberg D, Hoffmeister B, Amling M. Bisphosphonattherapie assoziierte. *Kiefernekrosen Deutsches Arzteblatt* 2006;46:A3078-80.
 10. Mavrokokki T, Cheng A, Stein B, Goss A. Nature and frequency of bisphosphonate-associated osteonecrosis of the jaws in Australia. *J Oral Maxillofac Surg* 2007;65:415-23.[CrossRef]
 11. Khan AA, Sandor GK, Dore E, Morrison AD, Alshali M, Amin F, et al. Bisphosphonate-associated osteonecrosis of the jaw—literature review. *J Rheumatol* 2009;36:478-90.[Abstract/Free Full Text]
 12. Reid IR, Cundy T. Osteonecrosis of the jaw. *Skelet Radiol* 2009;38:5-9. [CrossRef]

